

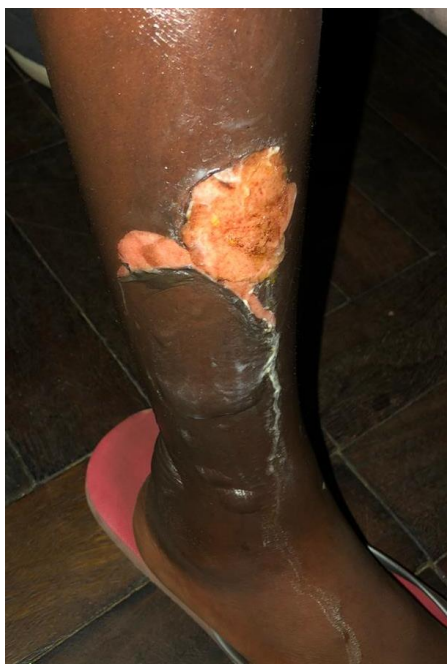eKasi Wound Care by WhatsApp 2020

**Case 1 Andile & the Hot Water
(Deep Partial Thickness Burn)**

**ActivHeal Aquafiber Extra +
PIP HALO Probiotic Skin Care**





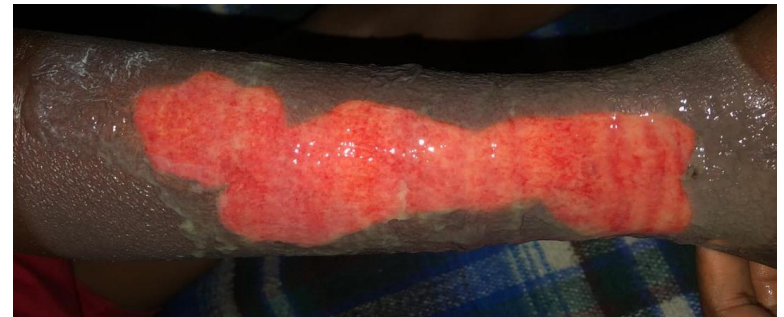
Andile's leg Friday 24th July post a game of Friday football
Scalded with boiling water on Thursday 23rd July.
His younger sister accidentally poured kettle water
over his leg, rather than into the bathing basin...
Andile is 10yrs old, his sister Sisipho is 8yrs old



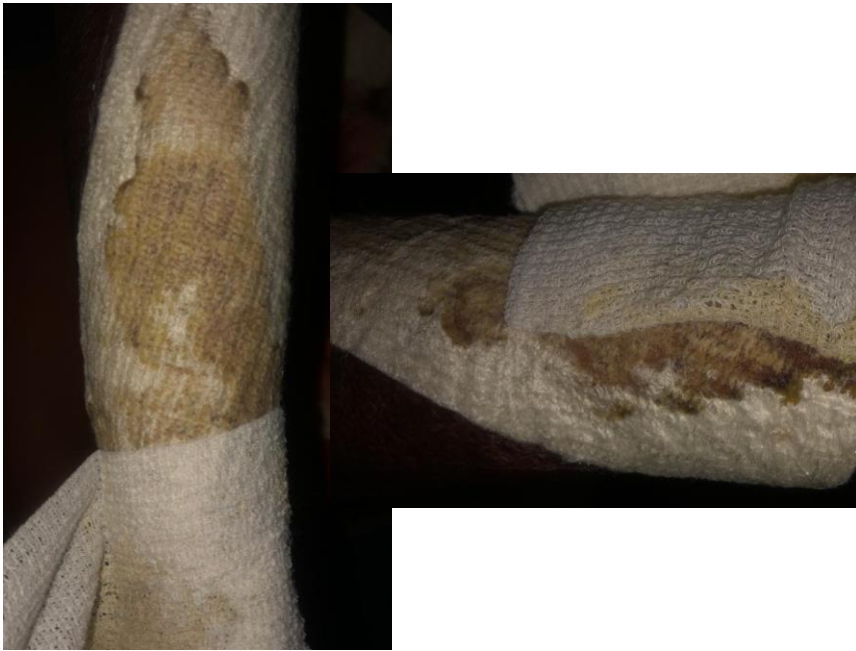Neither Aunt Priscilla, nor Andile wanted to go to Hospital &
Aunt Priscilla had the following items on hand – food wrap
+ SSD Cream. Between Durban & SOWETO, we put a
'clean the wound' plan in place via WhatsApp - SSD Cream
+ food wrap + bandage - until Monday



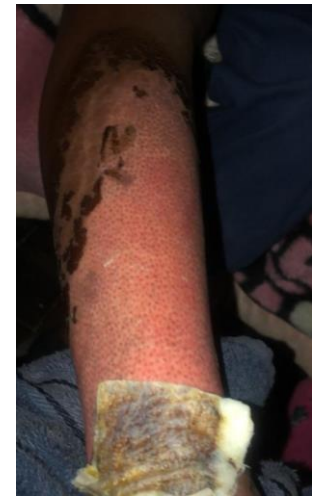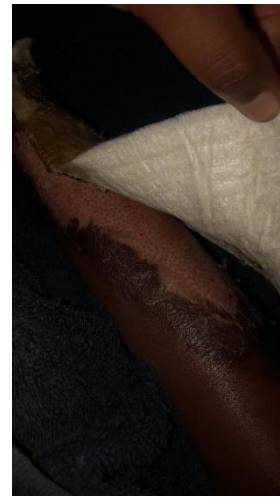After getting it wrong – the WhatsApp instruction was
SSD Cream + food wrap + bandage
We finally got it right – via WhatsApp... 😊



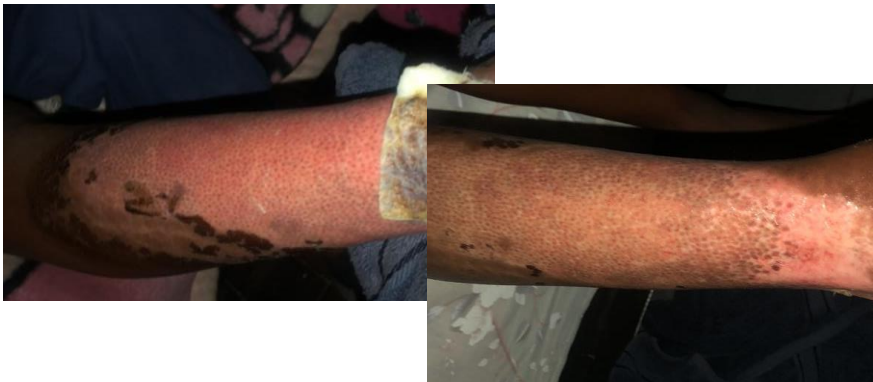By Monday 27th July, operation 'clean the wound' was
complete. Andile experienced no signs of infection
throughout this case study & is young, fit & healthy



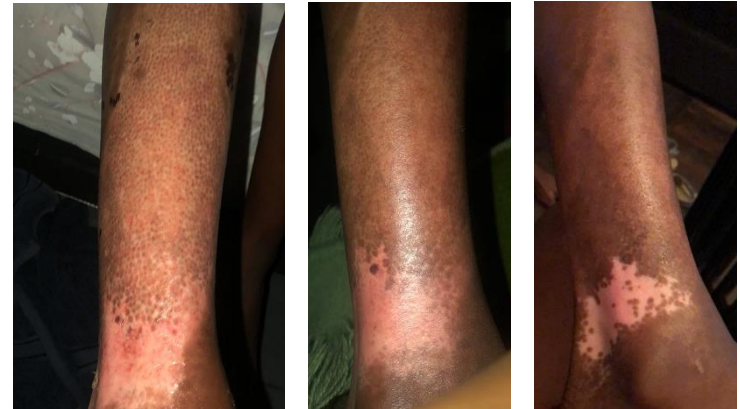On Monday 27th (pm), the burn was washed with PIP HALO Wound & Skin Wash, to remove all SSD cream, sprayed with PIP HALO Probiotic Spray & dressed with Aquafiber Extra + bandage. By Friday 31st July, complete fusion had occurred...



By Wednesday 5th August (Day 13 post burn & Day 9 post application of Aquafiber Extra) the dressing was ready to 'lift' across most of the wound surface – a small piece remained on the deeper area for 1 more day



From Wednesday 5th August to Friday 14th, melanocyte recovery (pigmentation) had progressed nicely. The PIP HALO Wash + Probiotic Spray were used daily.



Further progress has been made from the 14th August through the 22nd August up to the 17th September 😊

OBJECTIVES VS OUTCOMES – 23/09/20

- Simple Protocol for Home Use
- Single Application Dressing – No Dressing Changes
- Minimise Disruption to the Wound
- Mimic Hoekstra Effect
- Minimise Pain & Discomfort
- Full Pigmentation/Melanocyte Recovery
- Return to Normal Activities as Soon as Possible